



**PATIENT**

Jamocha Rupp

**SPECIES**

Feline

**BREED**

Bermese

**SEX**

Male Neutered

**AGE**

22 years

**WEIGHT**

11.5lbs

**INTERPRETED BY**

Maggie Machen  
Lamy, DVM, DACVIM  
(Cardiology)

**IMAGING PERFORMED BY**

Jenna Walsh, CVT

**HOSPITAL NAME**

West Hills Animal  
Hospital

**REFERRING VET**

Dr. Cole

**INVOICE**

30217

**DATE**

4/12/23

**PRESENTING CLINICAL SIGNS**

History: Grade 4/6 heart murmur with gallop rhythm. Syncopal event noted on 4/11/23.

**ELECTROCARDIOGRAPHIC FINDINGS**

A six lead ECG is available at 25mm/s; 10mm/mV. The average heart rate is 140bpm (range 115-150bpm). The rhythm is sinus in origin, with a p for every QRS complex and vice versa. The P wave morphology is positive with a normal dimension. Normal PR. The QRS morphology is positive with normal dimension. MEA is normal. No ectopic beats, pauses or dysrhythmias observed.

ECG diagnosis: Normal sinus rhythm with overall bradycardia; rule out high vagal tone v early sinus node dysfunction.

**ECHOCARDIOGRAM FINDINGS**

2D, m-mode, color flow and doppler imaging is available. The left ventricular wall is largely normal with regions of borderline hypertrophy. There is a diffusely hyperechoic endocardium. The papillary muscles appear remodeled. No significant hypertrophy seen. The left atrium is mildly dilated and bulbous in appearance. The mitral valve is normal in structure with mild MR. The right atrium is normal. The right ventricle is normal. No TR. Blood flow through the LVOT and RVOT is normal on Spectral; however, the an intermittent LVOTO is suspected on 2D imaging. No pleural or pericardial effusion seen. No obvious cardiac tumors.

**CARDIAC CHART**

| FELINE CARDIAC PARAMETERS | BODY WEIGHT (kg) | HR (BPM)                        | IVSd (cm) (Moise, Pipers)                | LVIDd (cm) (Moise, Pipers) | LVWd (cm) (Moise, Pipers) | FS (%)      | EF (%) |
|---------------------------|------------------|---------------------------------|------------------------------------------|----------------------------|---------------------------|-------------|--------|
| NORMAL PARAMETER          | -----            | 150-240                         | 0.35-0.55                                | <2 (mean 1.5)              | 3.5-0.55                  | 35-67       | 80-100 |
| PATIENT                   | 5.2              | 130                             | 0.53                                     | 1.59                       | 0.55                      | 50          | 85     |
| FELINE CARDIAC PARAMETERS | LA/AO (Boon)     | LA/AO HEART BASE (Swe) (Abbott) | LA 2D short axis Base view (cm) (Abbott) | LVOT VEL (m/s)             | RVOT VEL (m/s)            | E max (m/s) |        |
| NORMAL                    | <1.5             | <1.3                            | <1.2                                     | <1.6                       | <1.3                      | <0.9        |        |
| PATIENT                   | 1.7              | 1.6                             | 1.6                                      | 1.2                        | 0.95                      | NM          |        |

*\*Note: All measurements based upon multi-modal images and methods. An average value is reported.*  
 Adapted from June Boon, Veterinary Echocardiography, 1998  
 Abbott J & MacLean H JVIM 2006;20: 111-119, Moise et al. Am J Vet Res 47:1476, 1986. Pipers et al. Am J Vet Res 40:882, 1979.

**INTERPRETATION OF THE FINDINGS & FURTHER RECOMMENDATIONS**

Early unclassified cardiomyopathy is suspected, based upon mild atrial dilation and a lack of significant LV pathology. An intermittent LVOTO is suspected based upon 2D imaging, which may cause a murmur depending on heart rate. The LA is mildly enlarged, suggest relatively low risk for complication. No additional issues are identified.

The ECG shows a relatively low resting heart rate, dropping to 115bpm briefly. The rhythm appears sinus in origin which is most consistent with either high vagal tone or sinus node dysfunction. Consider a stress or atropine challenge in this case to assess for an adequate



**PATIENT**

Jamocha Rupp

**SPECIES**

Feline

**BREED**

Bermese

**SEX**

Male Neutered

**AGE**

22 years

**WEIGHT**

11.5lbs

**INTERPRETED BY**

Maggie Machen  
Lamy, DVM, DACVIM  
(Cardiology)

**IMAGING PERFORMED BY**

Jenna Walsh, CVT

**HOSPITAL NAME**

West Hills Animal  
Hospital

**REFERRING VET**

Dr. Cole

**INVOICE**

30217

**DATE**

4/12/23

response. If high vagal tone is confirmed, neurologic/GI disease, etc should be considered as a possible cause. If the response is minimal, this would suggest sinus node dysfunction.

These findings do not clearly explain a recent episode, although the bradycardia is somewhat concerning. Consider other possibilities in this senior cat; however, if the HR does not stimulate adequately this may be related. In this instance treatment options are limited, and referral for discussion with a local Cardiologist would be suggested.

Prognosis is guarded and highly variable, with many cats with occult cardiomyopathy remaining asymptomatic for extended periods of time,

Monitor for any signs of progressive heart disease at home including change in breathing rate or effort, signs of a blood clot event and/or lethargy/syncope going forward.

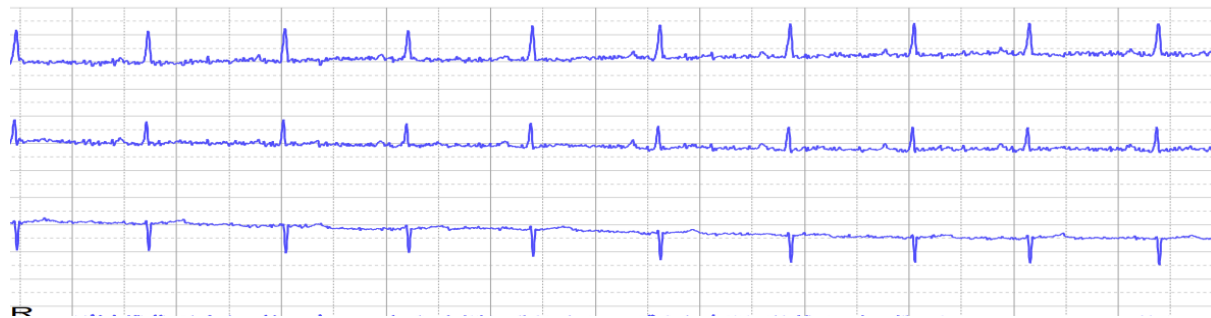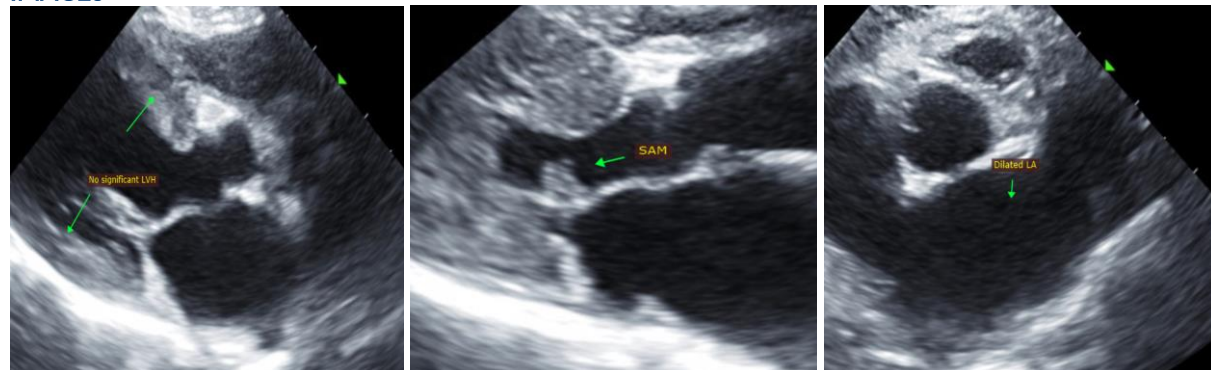
Anesthesia is not advised due to bradycardia.

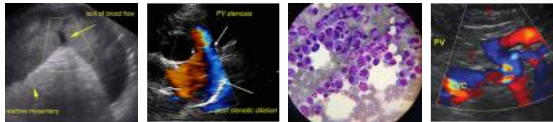
**PLAN**

Baseline BP is recommended. Consider alternative causes of episodes. Consider response to stress and/or atropine to determine if high vagal tone is present (0.04mg/kg atropine IV or IM and assess response). If response is lackluster, sinus node dysfunction is diagnosed, and referral should be considered. If response is normal, causes of high vagal tone such as neurologic disease must be considered.

Recommend recheck echocardiogram in 6 months to screen for progression, sooner if clinical signs arise.

**IMAGES**





**PATIENT**

Jamocha Rupp

**SPECIES**

Feline

**BREED**

Bermese

**SEX**

Male Neutered

**AGE**

22 years

**WEIGHT**

11.5lbs

**INTERPRETED BY**

Maggie Machen  
Lamy, DVM, DACVIM  
(Cardiology)

**IMAGING  
PERFORMED BY**

Jenna Walsh, CVT

**HOSPITAL NAME**

West Hills Animal  
Hospital

**REFERRING VET**

Dr. Cole

**INVOICE**

30217

**DATE**

4/12/23

The information and recommendations provided are based on the images presented by the referring veterinarian. No evaluation can be communicated regarding pathology that was not visible in the image/video clips provided.

Thank you for this referral. This report was generated using transcription software, and minor dictation errors may be present. If the clinical or image interpretation does not parallel your findings or if I can be of any further assistance, please contact me.

Maggie Machen Lamy, DVM  
Diplomate of the American College of Veterinary Internal Medicine (Cardiology)  
info@sonopath.com